



Man vs. Machine – guided and non-guided approach in implantology

Authors:

Christian Mehl, Prof. Dr.
Florian Hagemoser, Dental technician
Sönke Harder, Dr, PhD

Address:

Wimpole Street Dental Clinic
38 Queen Anne Street
W1G 8HZ
London
United Kingdom



Short title

Guided implantology

Corresponding address:

Wimpole Street Dental Clinic

38 Queen Anne Street

W1G 8HZ

London

United Kingdom

Tel +44 (0) 20 37457455

Email christian.mehl@wimpolestreetdentalclinic.co.uk

Man vs. Machine – guided and non-guided approach in implantology

Summary

Due to the rapid development of supporting software programs in all areas of dentistry and ever new possibilities to link the analogue with the digital world, there are now incredible treatment and planning options for the modern practitioner. The shift from the actual treatment chair-side to digitally pre-planning treatments requires increasing knowledge from dentists regarding the latest software programs and especially their interfaces with one another. But not only is the profession changing fast for dentists, the level of knowledge demanded from dental technicians has also increased dramatically. This article hopes to create some curiosity about this change with a little glimpse into the emerging world of digitalised implant dentistry.

Introduction

Poor long-term survival rates and the wish of many patients to receive fixed teeth have left removable solutions appearing as a second choice therapy [1]. Nevertheless, in particular when multiple teeth are lost, removable dentures are often chosen due to financial constraints. The resulting restoration is often unsatisfactory for functional, aesthetical and phonetical reasons [1-3].

Even carefully manufactured telescopic dentures on natural teeth may lose their function if the telescope-supporting abutment teeth are lost because of overloading, periodontitis or decay [1].

This article shows the surgical, prosthetic and laboratory procedure of two comprehensive rehabilitations with fixed screw retained bridges and discusses alternatives as well as advantages and disadvantages of this method. Particular attention is paid to the comparison of guided and non-guided implantation. To keep this article as concise as possible, the

authors do not want to present a comprehensive literature research in the introduction, but instead refer to the relevant literature [4] and the discussion below. With this article, we want to show at what amazing speed digitalisation has changed dentistry and what incredibly exciting possibilities there are today.

Case presentations

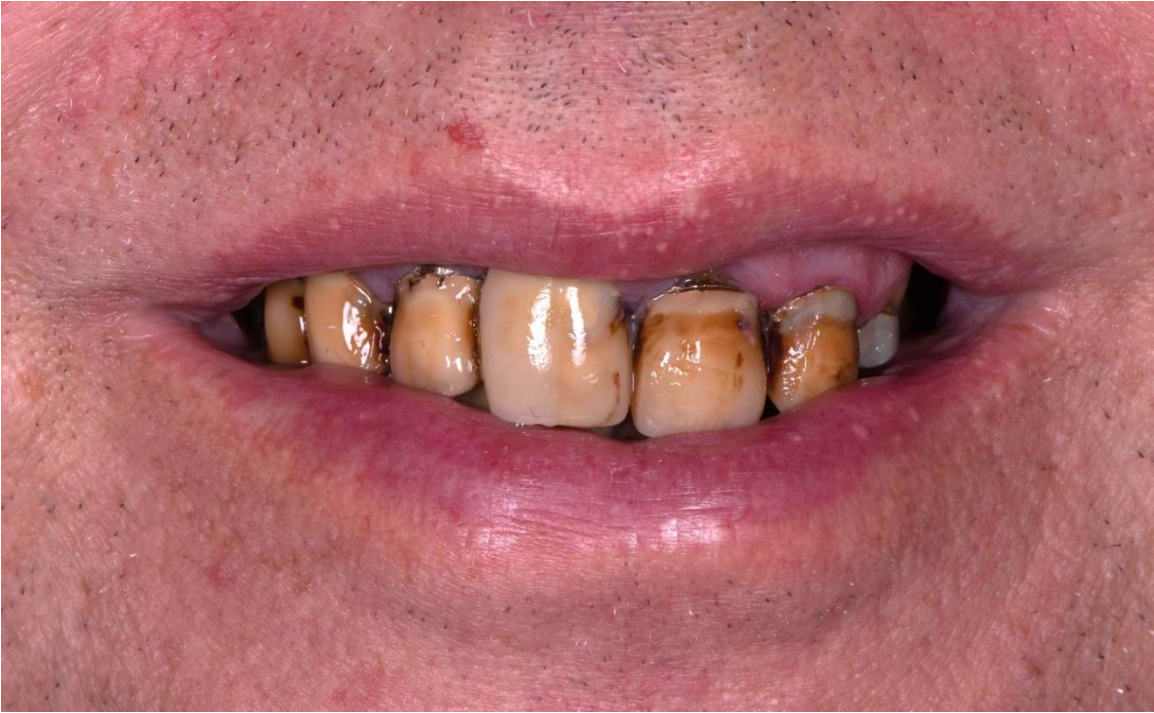Case Report 1 - Non-Guided Surgery

The 66-year-old male patient presented himself to our clinic in 2020. The general medical history was without any pathological findings. According to the patient, the dentures he was wearing were over 30 years old (Figure 1a-f).

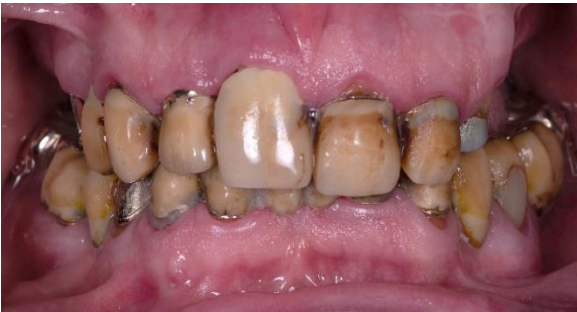Figure 1

Initial situation (a) patient smiling, (b) with retracted lips, (c) and (d) view from the lateral right and left, and (e) and (f) view from occlusal

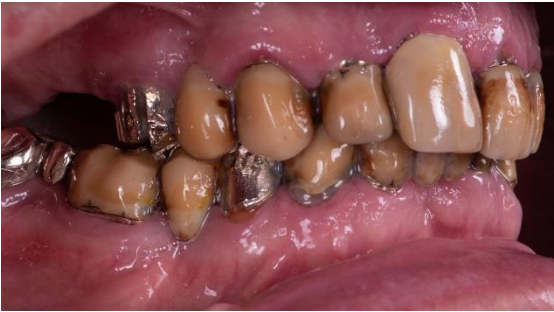(a) Patient smiling



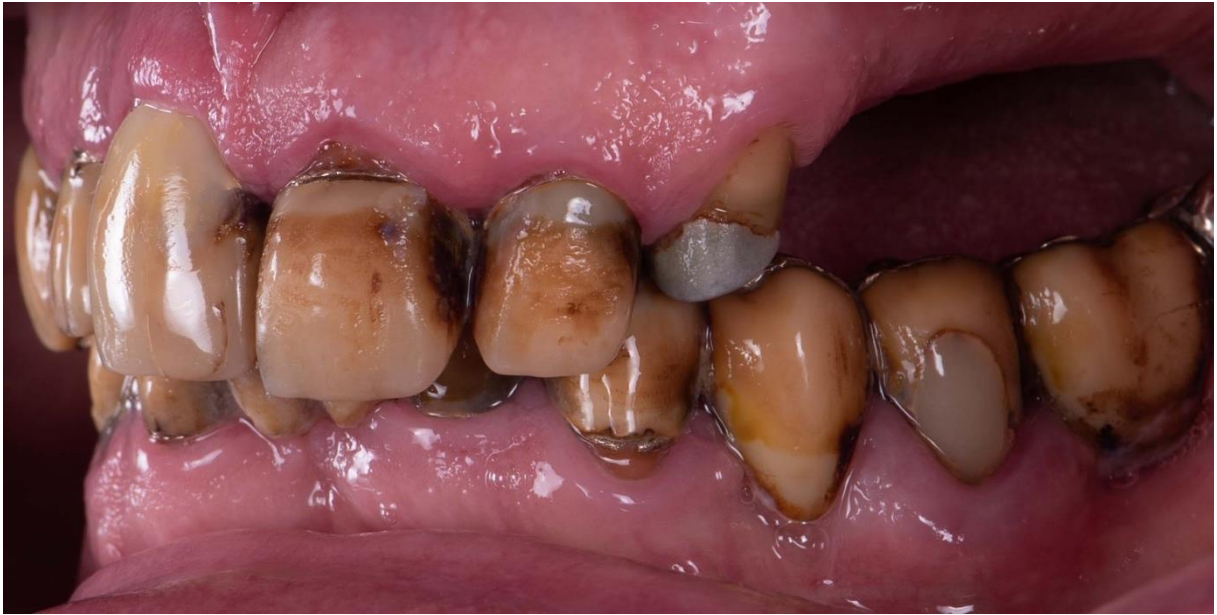(c) With retracted lips



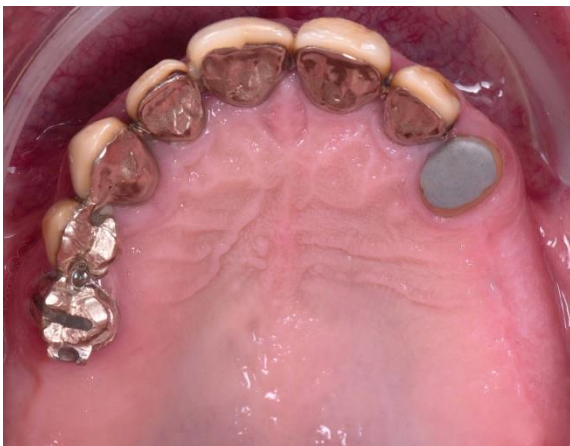(b) View from the lateral right



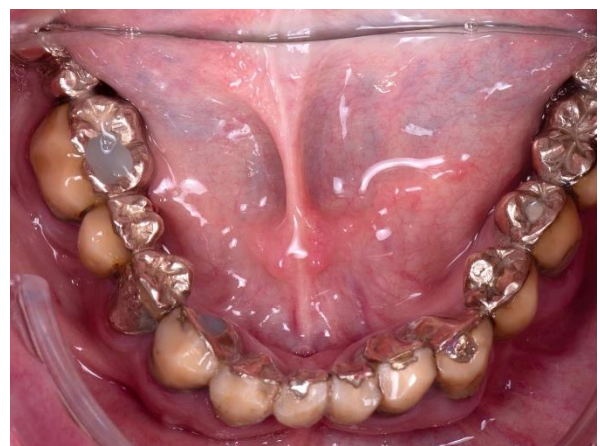
(d) View from the lateral left



(f) View from occlusal



(e) View from occlusal

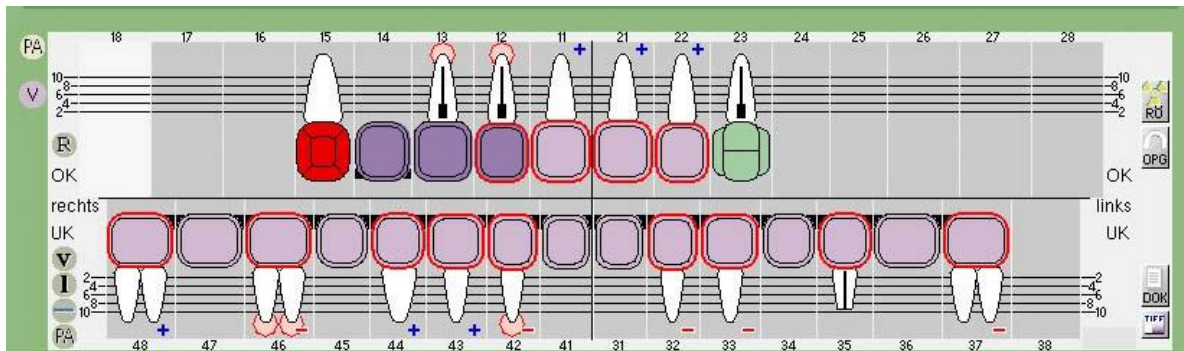


After the initial diagnosis (Figure 2a and b), and ethical consideration of the necessary extractions and discussion of all possible treatment options, it was decided to restore his lower with endodontic treatments of teeth 33 and 36, two tooth-supported bridges and one implant-supported bridge (Figure 3).

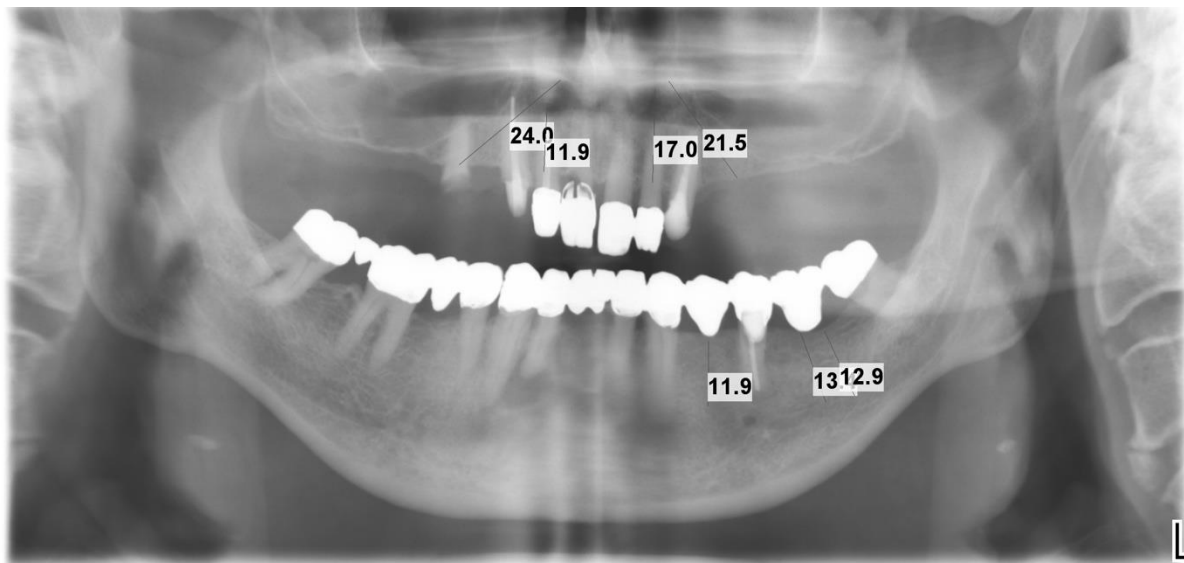
Figure 2

(a) Initial findings and (b) initial radiological situation in the OPG with length measurements from the initial examination indicating a possibility for the Comfour® concept

(a) Initial findings



(b) initial radiological situation in the OPG with length measurements



The option decided on for the upper jaw was to remove all the remaining teeth and restore function and aesthetics with a screw retained bridge on four implants (Camlog Comfour Concept; Figure 3). Together with the patient we decided that the majority of the treatment should be carried out under deep sedation.

Prior to the operation, a cone beam computer tomography (CBCT; Figure 4), a digital scan of the teeth and a photo status were recorded to plan the operation. The collected data was then used in three ways:

1. The digital implant planning by the dentist
2. The idealised digital framework for the smile of the patient ("smile design")

-
-
3. The transfer of the digital data from 1. and 2. into the analogue world by the dental technician (models, drilling template, preparation of the temporaries)

Figure 3

Treatment planning discussed with the patient

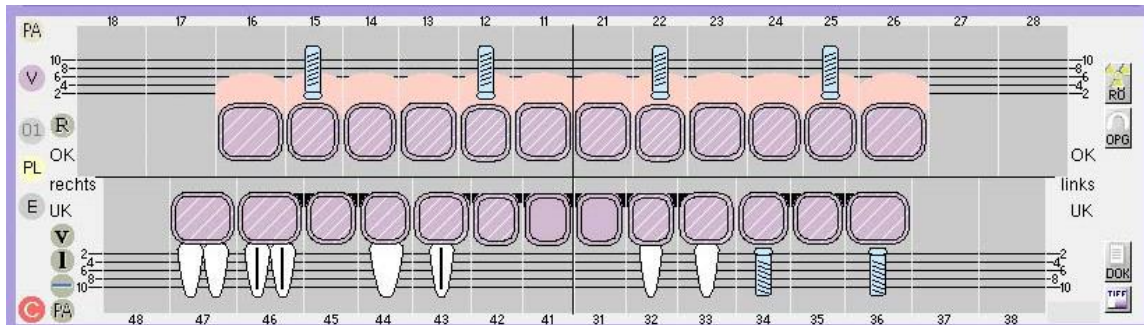
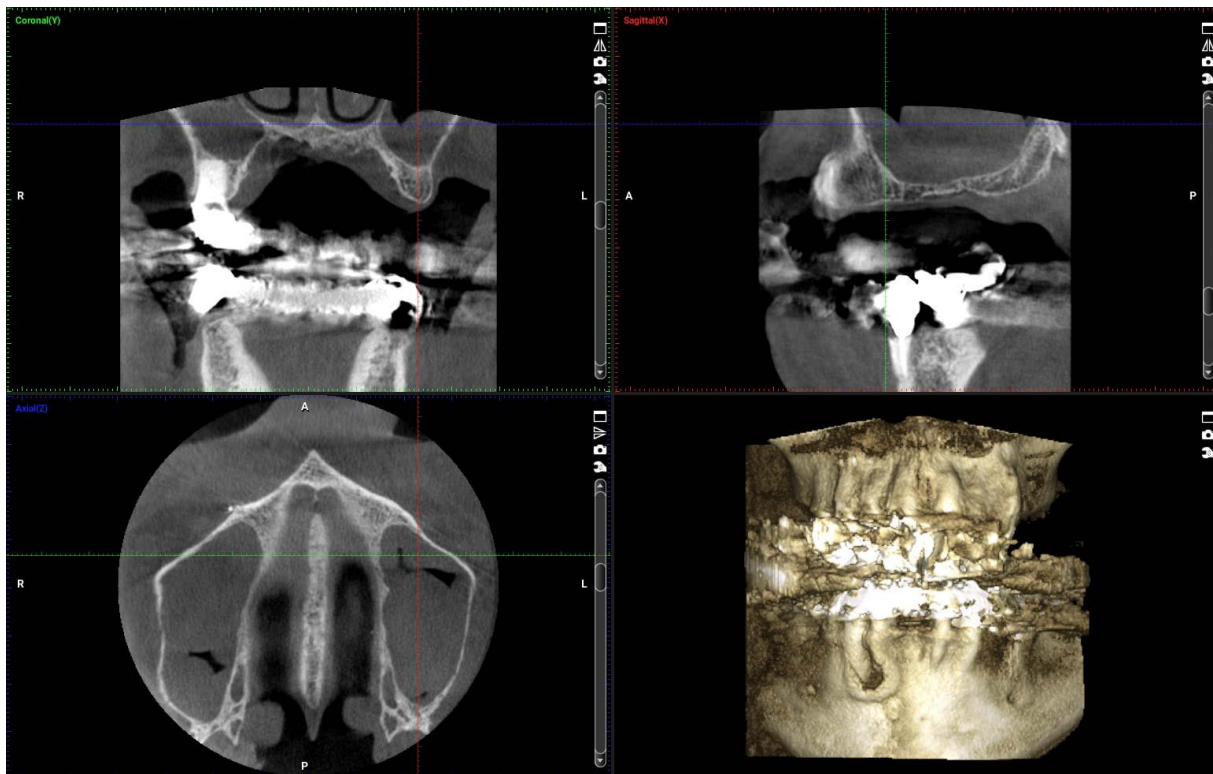


Figure 4

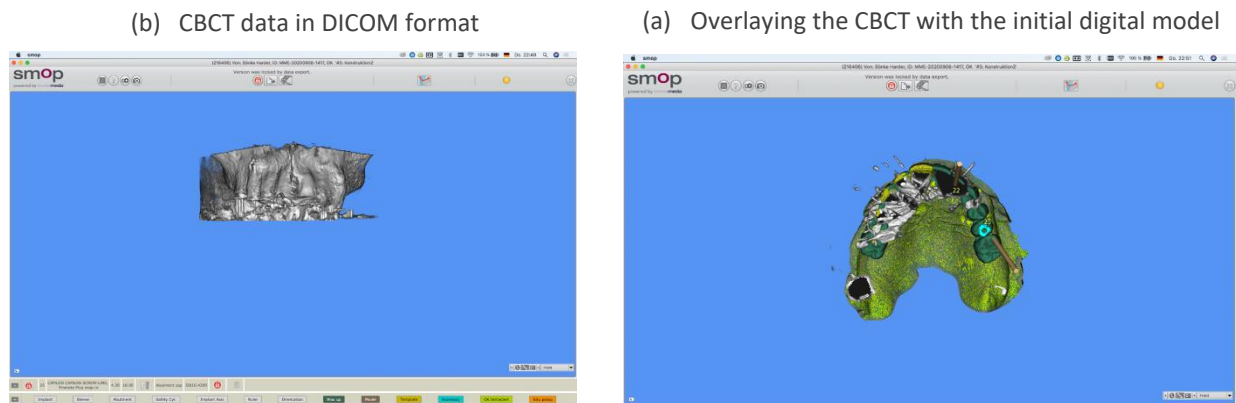
Start of the implantological planning with CBCT



The implant planning was carried out with a software program (SMOP, Swissmeda, Baar, Switzerland, Figure 5a and b).

Figure 5

Determination of the implant parameters in the implant planning program with (a) uploading the CBCT data in DICOM format and (b) overlaying the CBCT with the initial digital model, the digital model with the removed teeth, the wax-up / set-up with the implant axes and the scan-bodies.

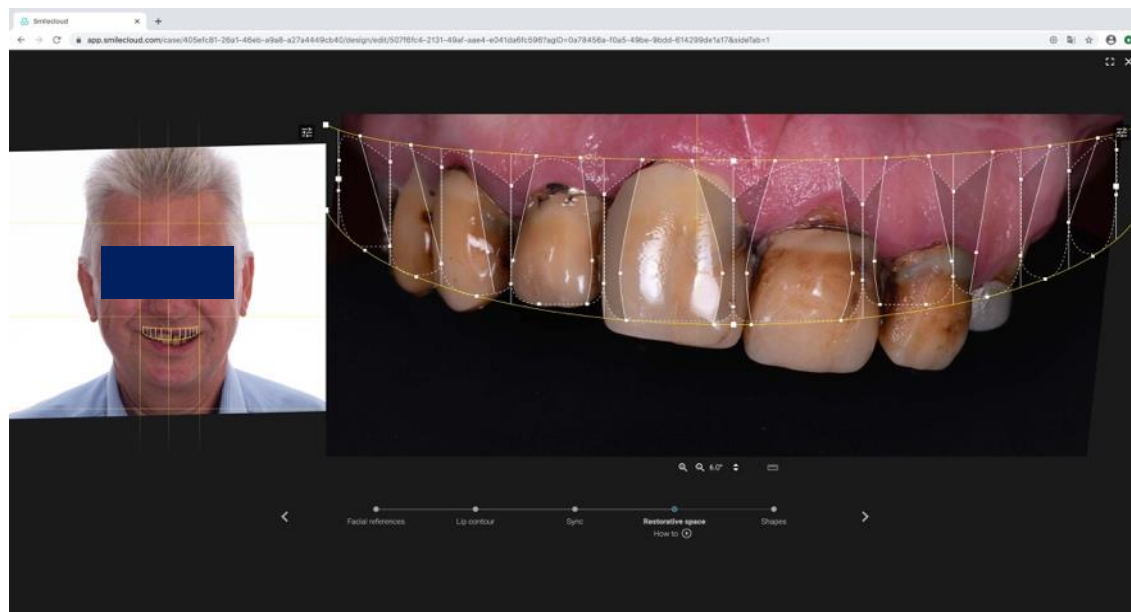


The digital set up made by the dentist as a guideline for the dental technician was also designed by a software program (SmileCloud, SmileCloud Biometrics; Figure 6a-c).

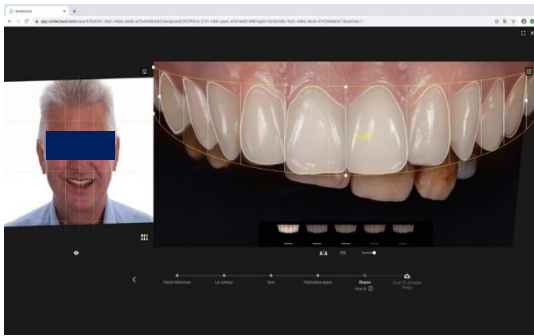
Figure 6

Uploading the photos into a digital smile design software (Smilecloud) with (a) initial image, (b) idealised digital design and (c) before / after analysis


(a) Initial image uploaded with digital smile design software (Smilecloud)



(c) Idealised digital design



(b) Before / after analysis

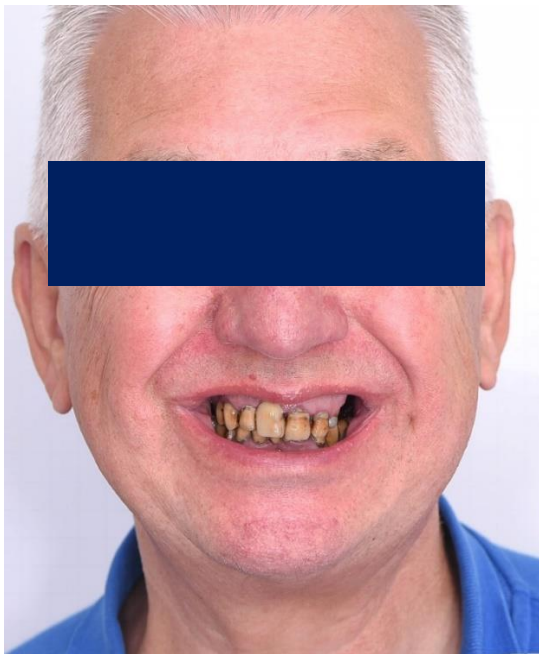

The final situation we wanted to achieve was created with another digital set-up done by the dental technician (Smile Design, Amann-Girrbach, Pforzheim, Germany; Figure 7a-i).

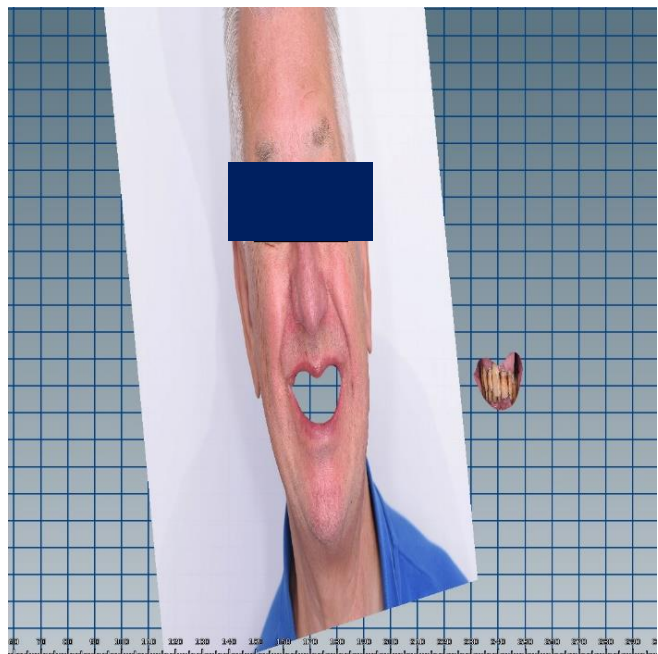
Figure 7

Planning of the temporary restorations in the dental laboratory with:

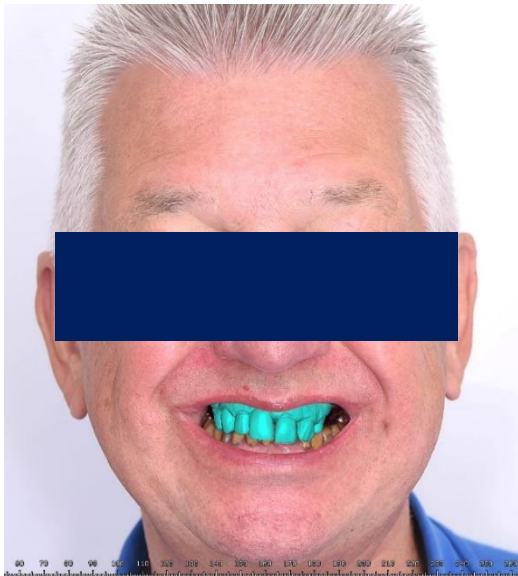(a) The initial situation



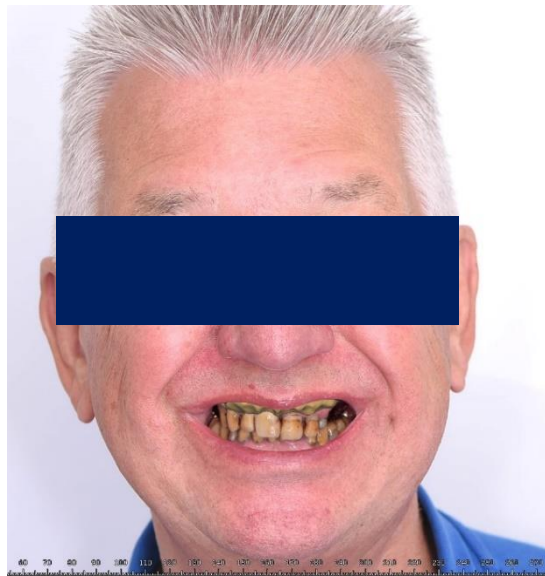(b) Cutting the teeth and gums from the smile image



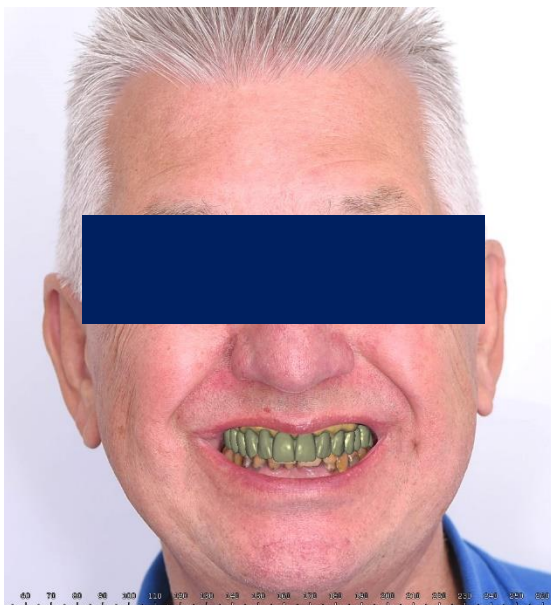(b) Superimposing the initial photo with the digital scan of the initial situation



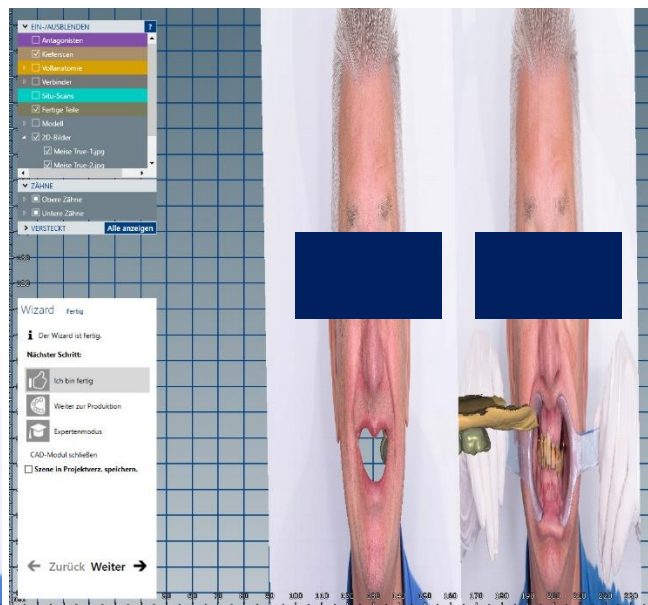
(d) Erasing the teeth and the gums with the aid of the digital smile design software



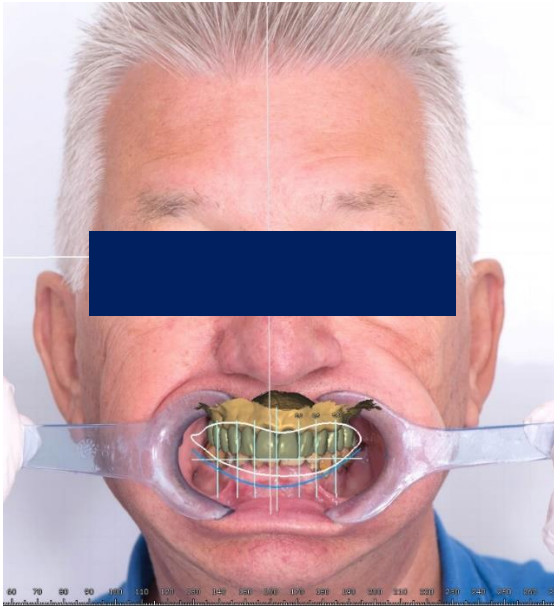
(f) Fully designed temporary



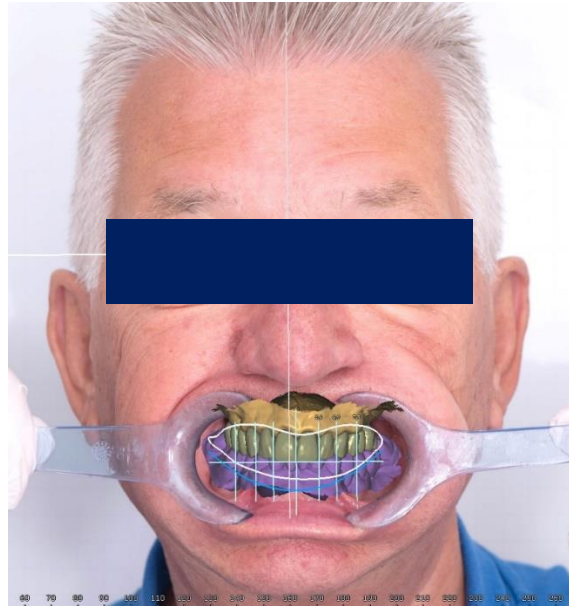
(e) A 3D rotation for the reader to better understand the superimposition of the individual data



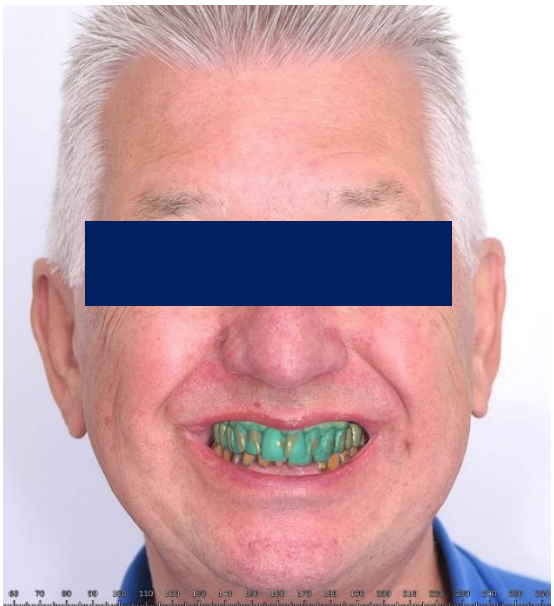(h) Checking the initial layout with the lip contours (white line)



(g) Fully modelled eggshell temporary in the lower jaw



(i) Check of the wax-up with an overlaid initial situation

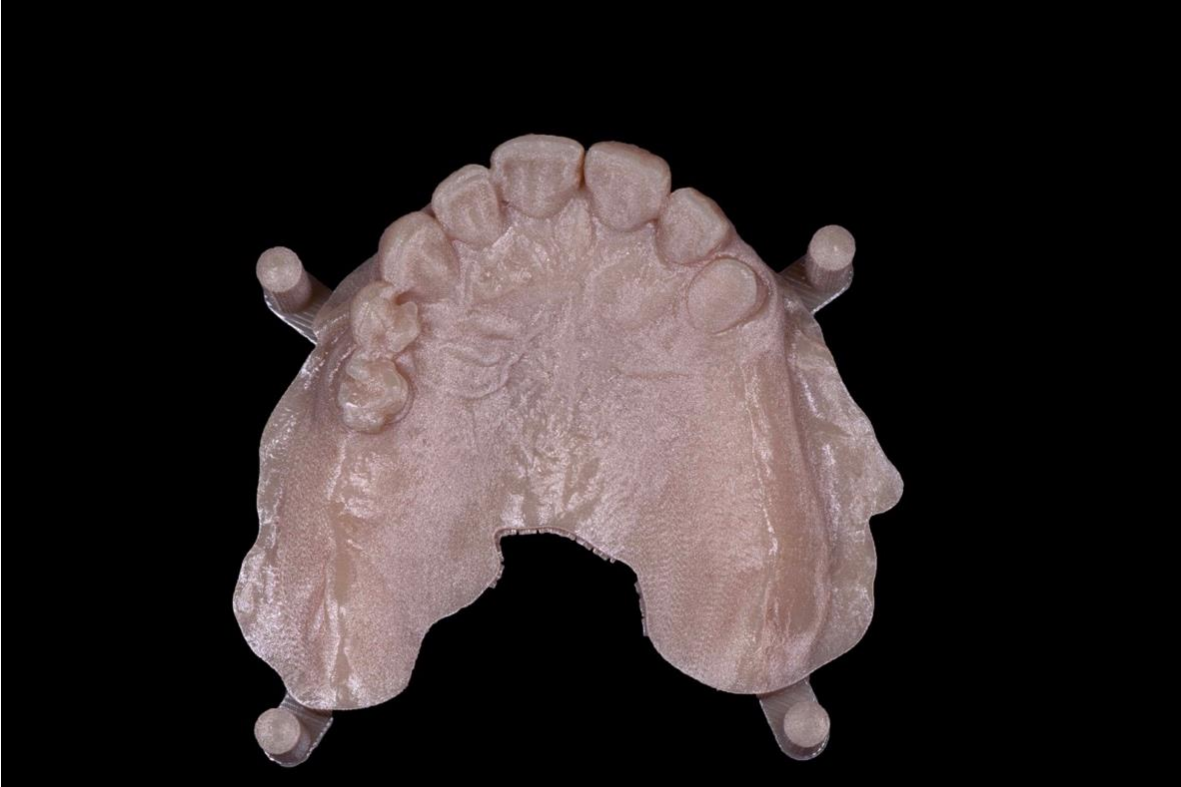

After the finalized digital planning had been accepted by the dentist, the models were then printed (3-D Medical Print, Lenzing, Austria; Figures 8a-8e), and the temporary was milled in the in-house laboratory from tooth-coloured PMMA (Figures 8f and g).

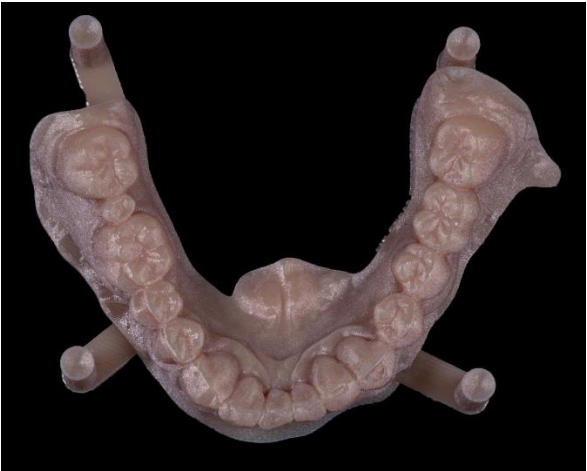Figure 8

Transfer of digital planning into the analogue world with:

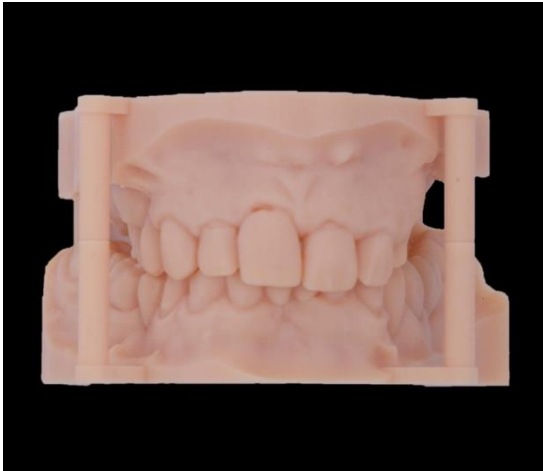(a) Printed upper jaw model



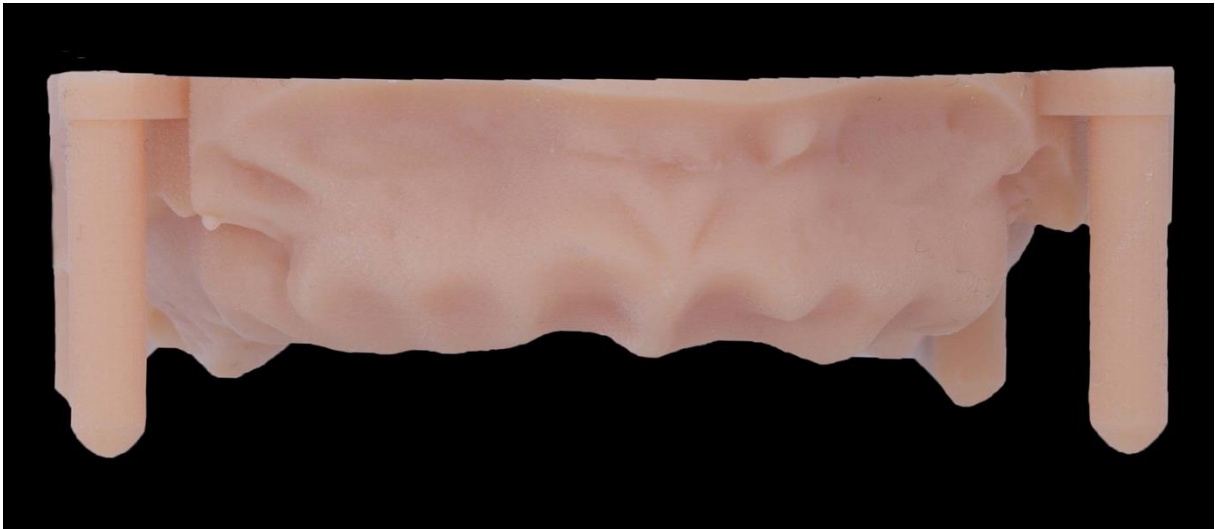(c) Printed lower jaw model



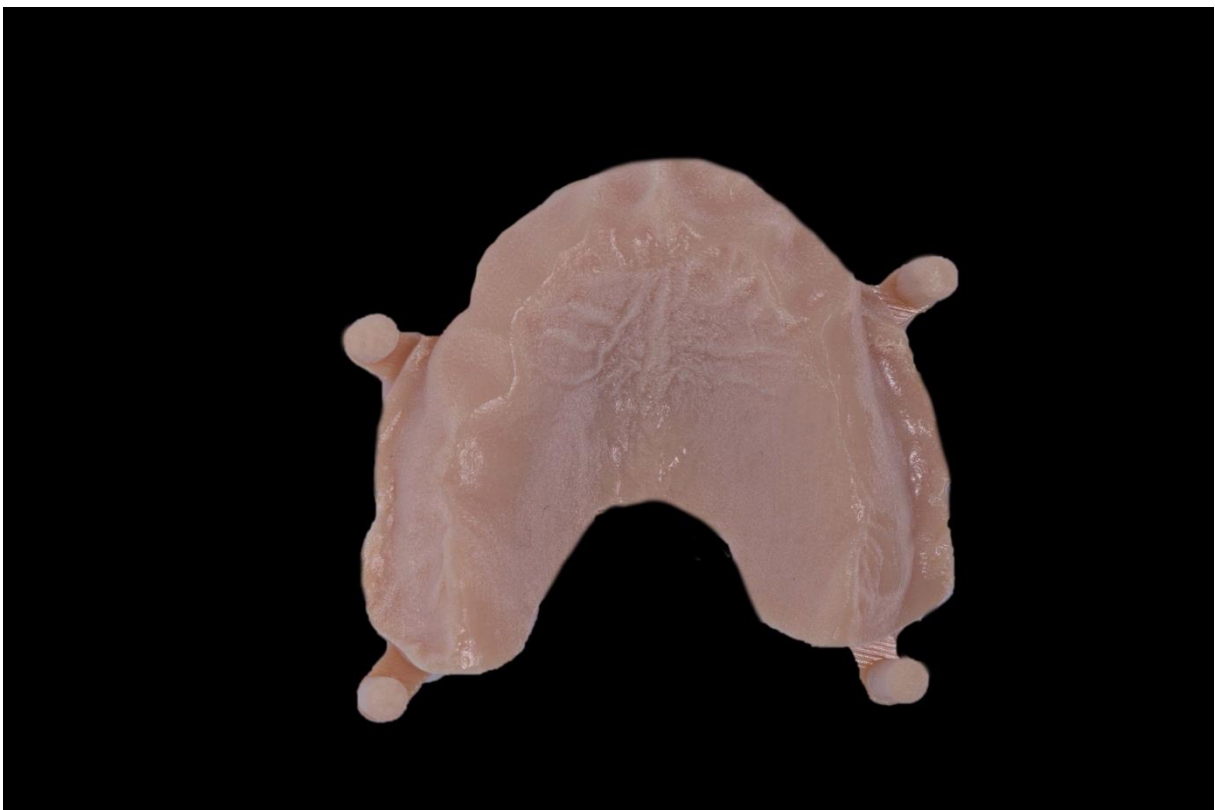(b) Models in occlusion



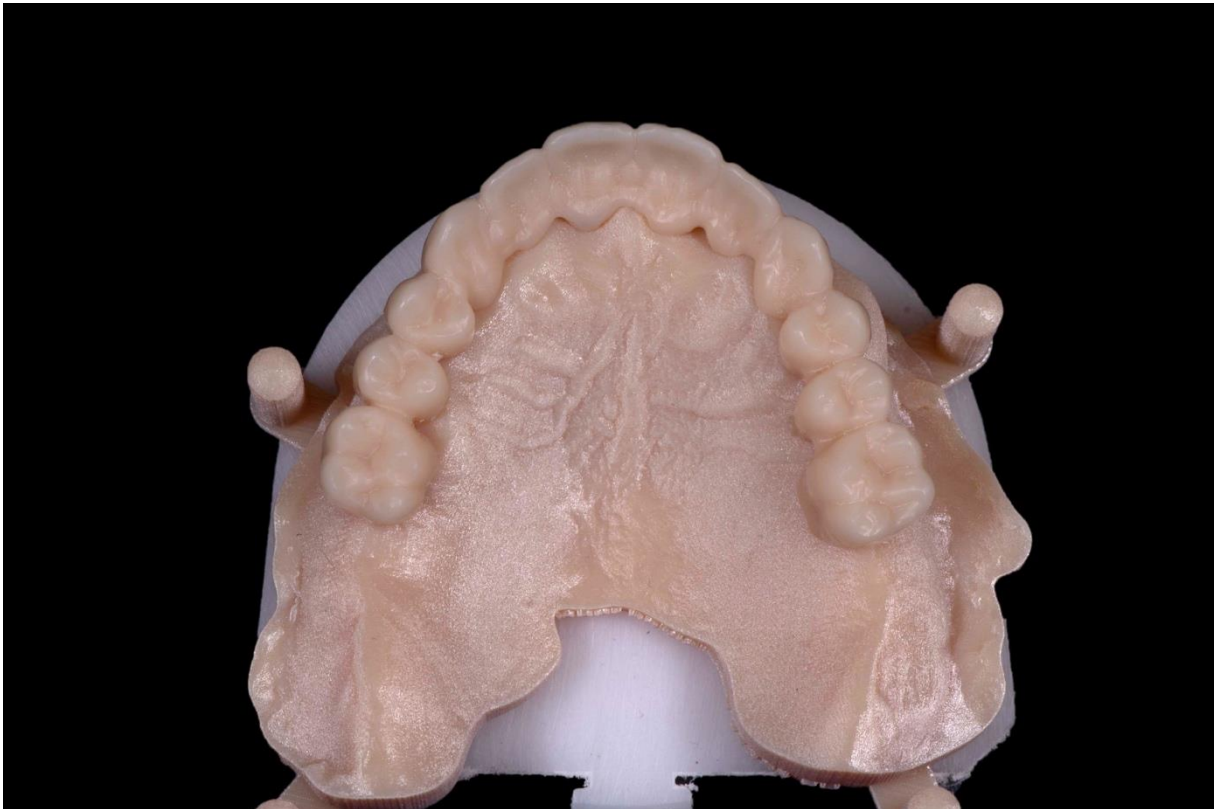(d) Digitally redacted printed model



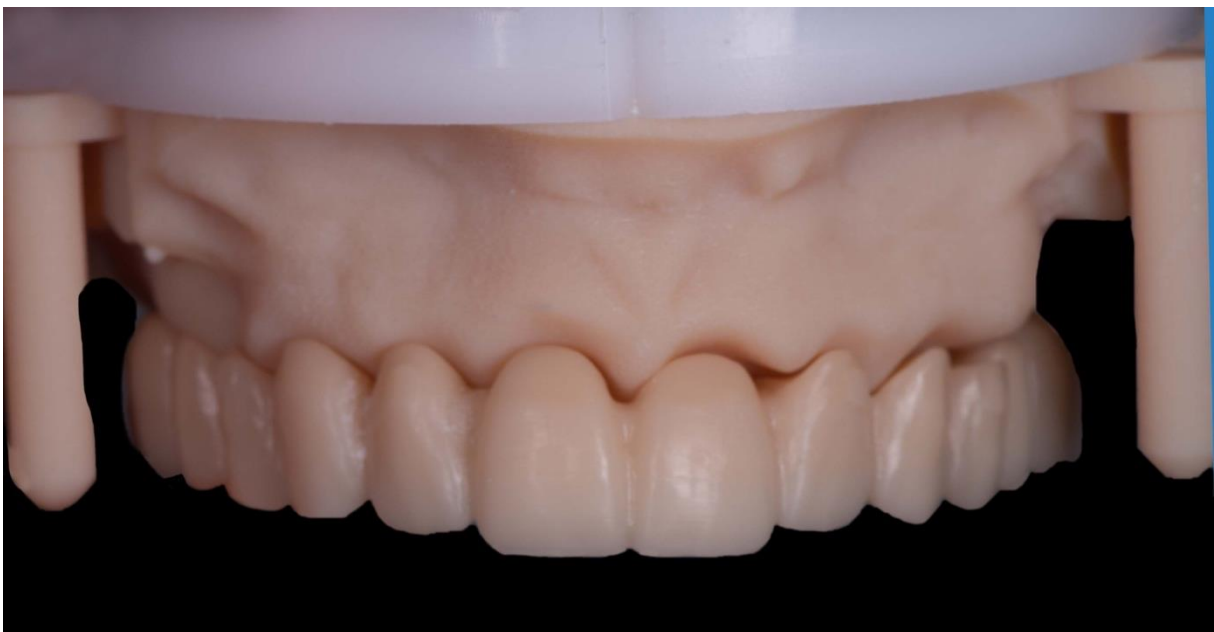(e) Digitally redacted model printed shown in occlusal view



(f) Milled PMMA temporary



(g) Milled PMMA temporary



An implantation with a guided drilling template was originally planned, but due to postal difficulties, the PMMA temporary had to be duplicated as a drilling template at short notice. Endodontic pre-treatment of the teeth 33 and 36 was performed in a separate appointment prior to the operation.

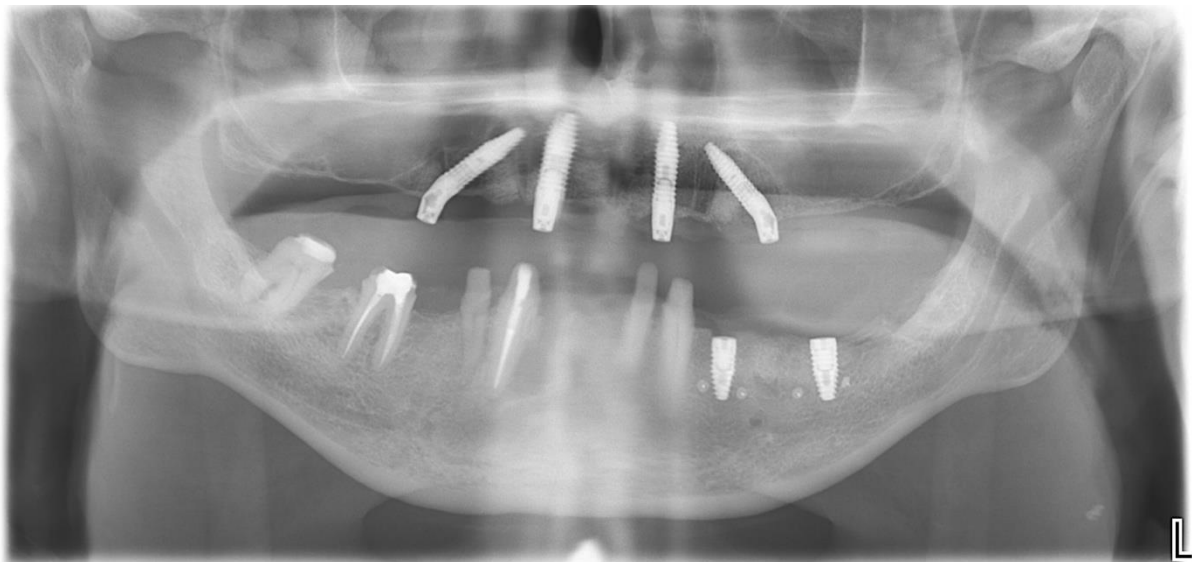
During a five and a half hour operation under deep sedation the remaining teeth in the upper jaw were completely removed. In the lower jaw the teeth 33, 32, 43, 44, 46 and 48 were prepared for the temporary and tooth 42 was extracted. Mucoperiosteal flaps were then prepared in the upper and lower jaw and, following the marking of the implant position, the implant cavities were drilled free hand using a drilling template (the duplicated PMMA temporary).

After inserting the implants (Camlog Progressive Line, Camlog, Basel, Switzerland) with a torque between 50-70 Ncm, a mesostructure was screwed into the implants with 20 Ncm. The extraction sockets were filled or covered with xenogeneic bone of bovine origin (BioOss, Geistlich, Baden-Baden, Germany) and membranes (Osseoguard, Zimmer Biomet, Palm Beach Gardens, FL, USA).

After closing the wound with sutures, an open tray impression was taken (Permadyne, 3 M Espe, Landsberg am Lech, Germany), whereby the implant impression posts were connected with an individually pre-bent orthodontic wire and composite (Ceramill, Amann-Girrbach, Pforzheim, Germany).

Then the bite was taken together with the PMMA temporary (R-SI-Line, Metall-Bite, R-Dental, Hamburg, Germany). After the patient woke up, a postoperative OPG was taken (Figure 9).

Figure 9
Postoperative OPG

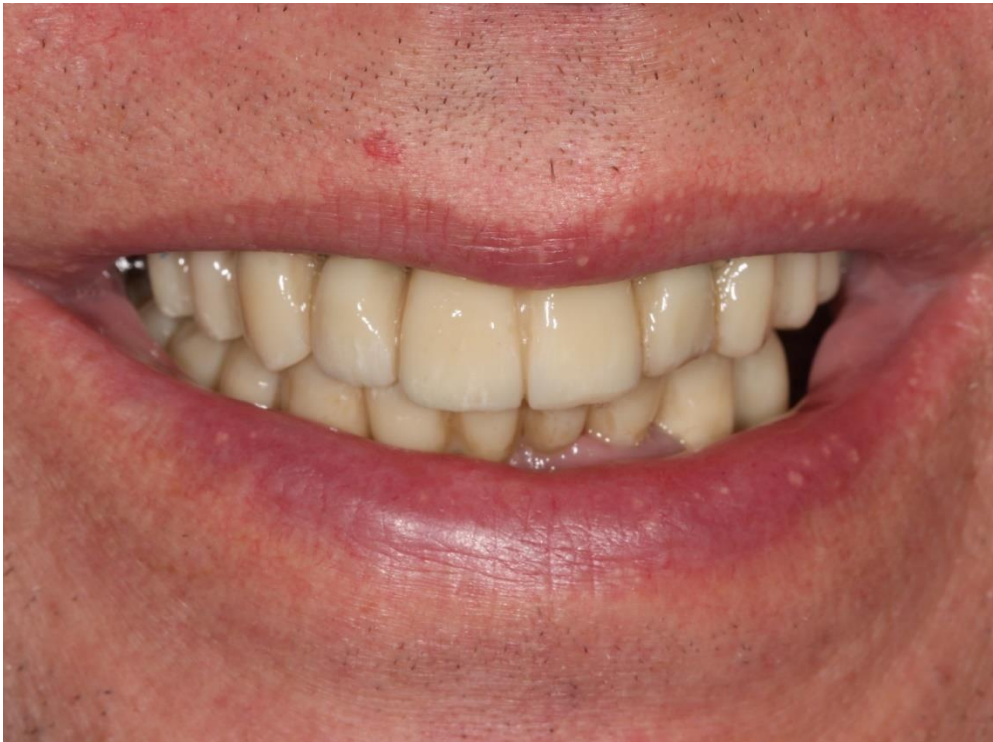

The impression and the temporary with the bite registration were given to the laboratory. The upper jaw implant model was produced in about 1.5 hours and titanium link abutments were inserted into the upper jaw temporary. Seven hours after the start of the operation, a screw retained bridge could be inserted with a torque of 10 Ncm (Figure 10a and b).

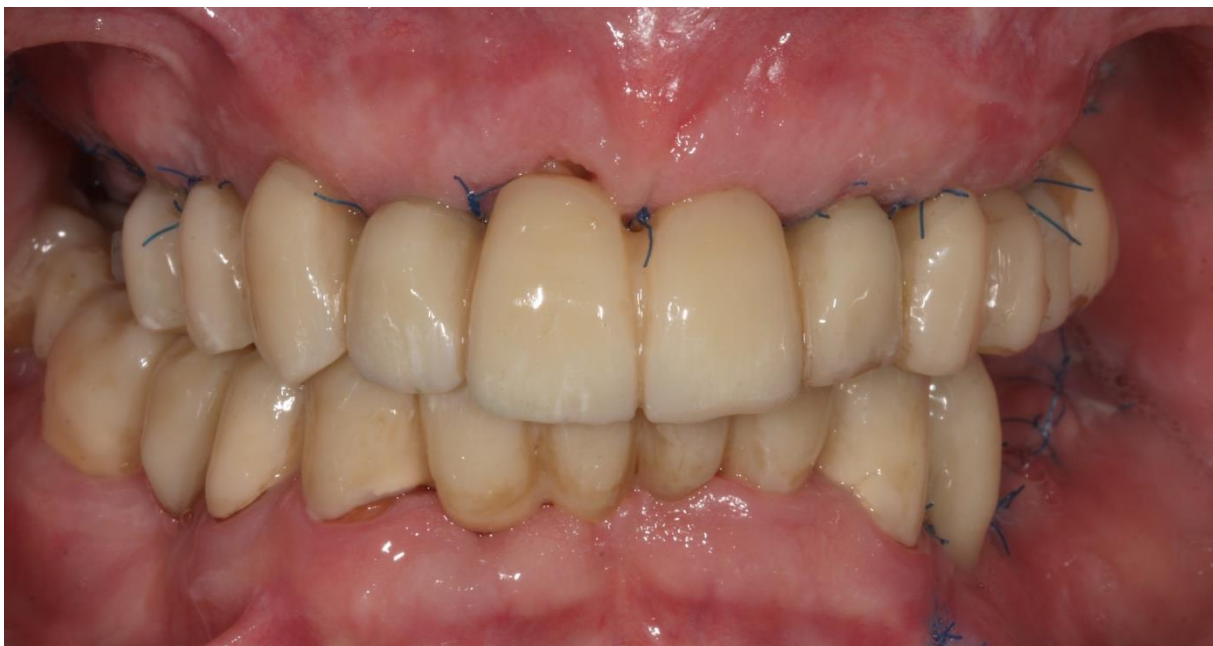Figure 10

Situation two weeks after the operation with

(a) Patient smiling



(b) With retracted lips



The access to the screw access holes was covered with sterile PTFE (Teflon) and composite (Tetric flow, Ivoclar, Schaan, Lichtenstein). The final restoration was placed three weeks after the operation (Figures 11 and 12a-c). The patient was asked to attend a regular, six-monthly recall.

Figure 11

Final restoration - a metal framework veneered with industrially prefabricated and individualised composite veneers

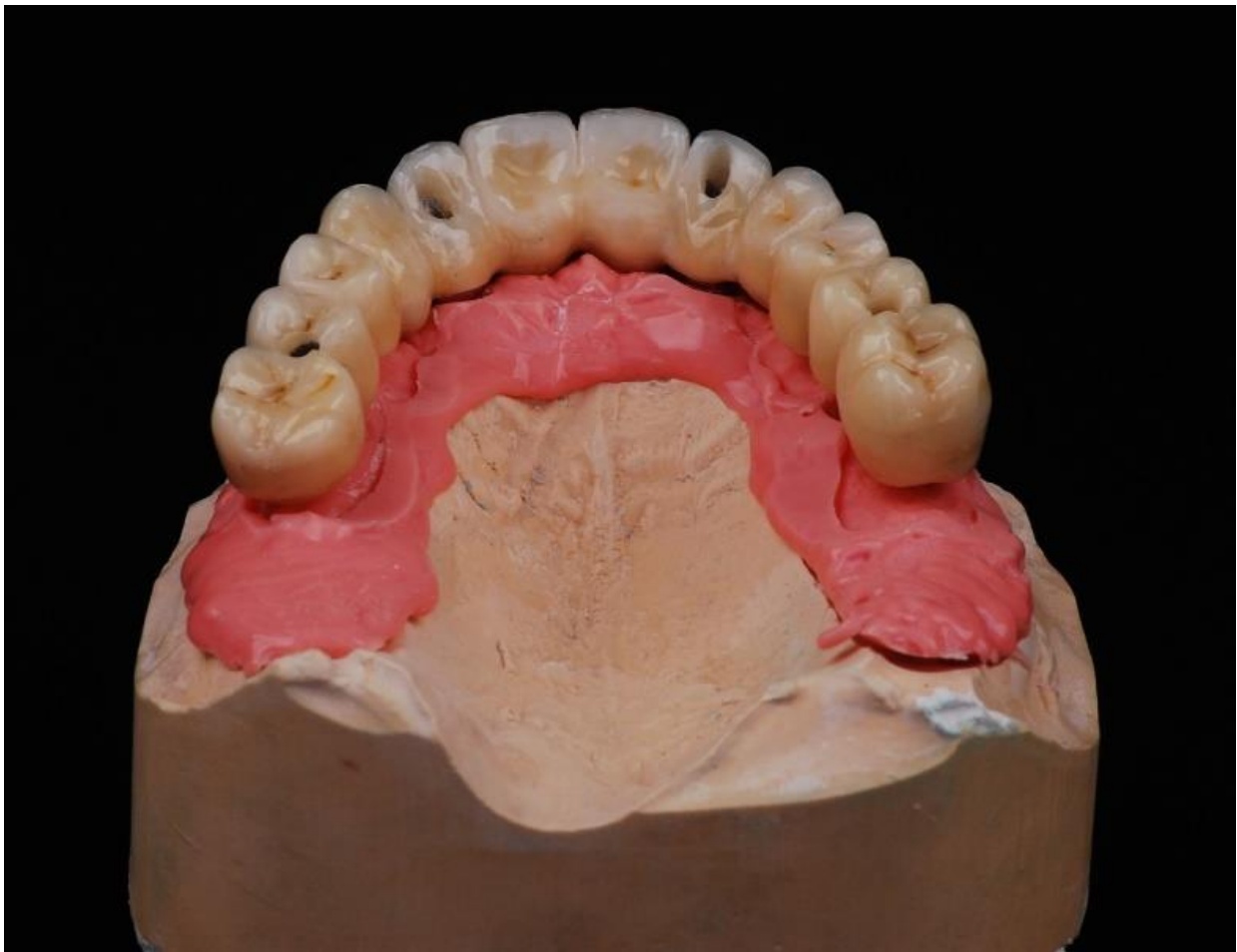
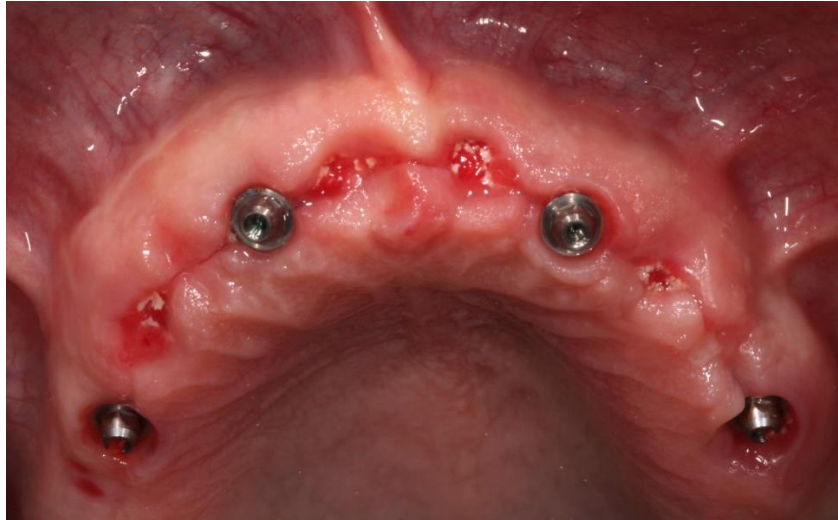
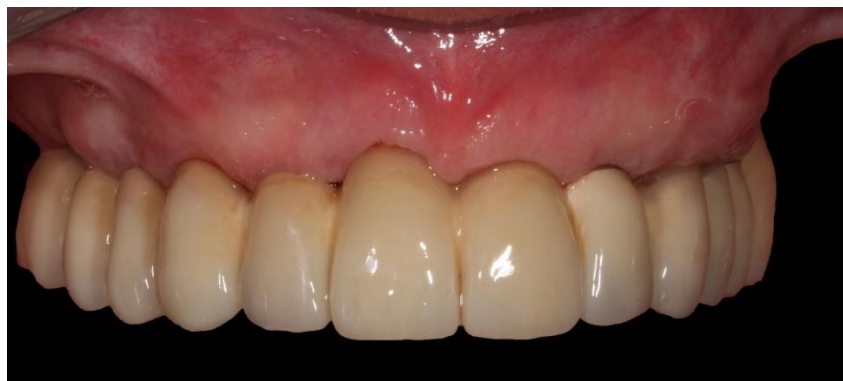Figure 12

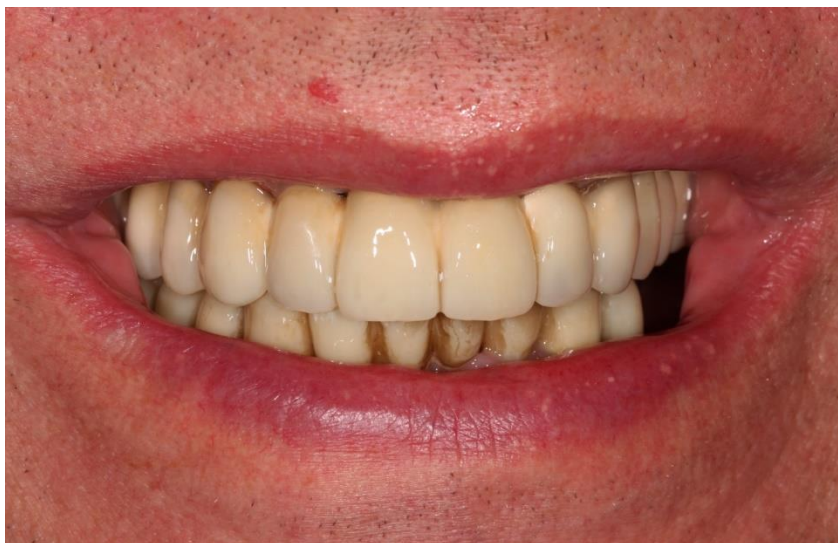(a) Upper jaw before placement of the restoration



(b) Placed screw retained bridge en-face



(c) Image of patient smiling (the lower long-term temporary in the lower jaw is discoloured due to the 14-day CHX rinsing)



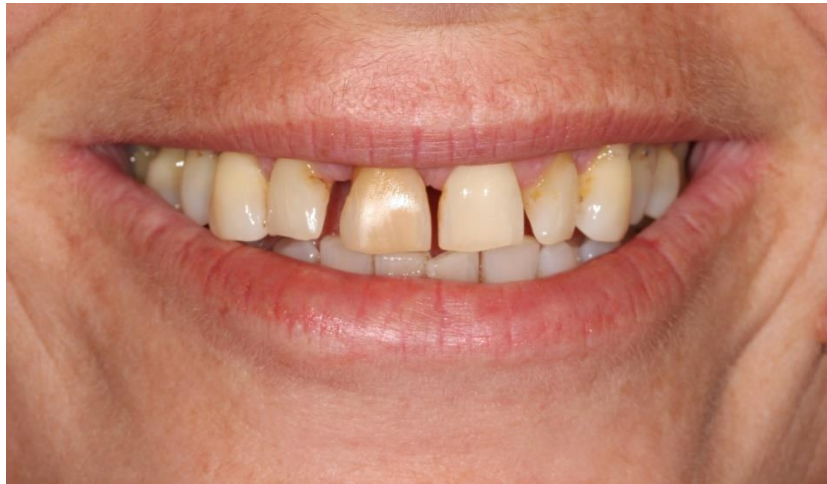Case Report 2 - Guided Surgery

The 47-year-old female patient attended our clinic in 2020. The general medical history was without pathological findings. The dental anamnesis and examination revealed a severe periodontal problem and several missing teeth (Figure 13a-c).

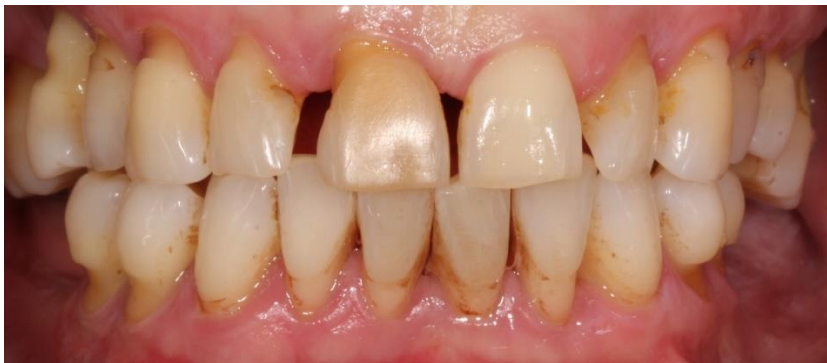Figure 13

Initial situation with (a) patient smiling, (b) with retracted lips and (c) initial OPG

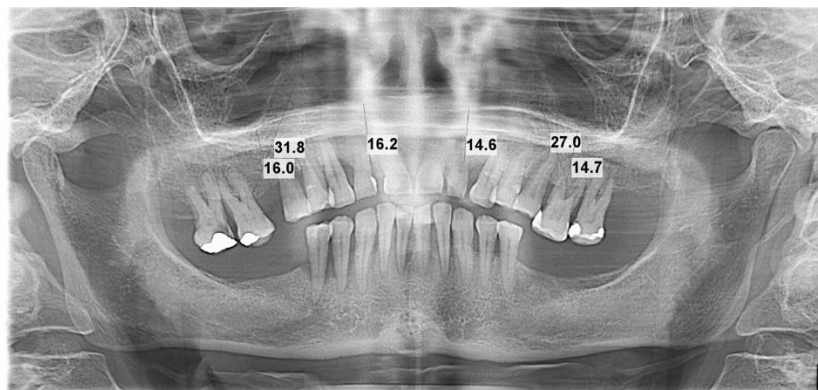
(a) Patient smiling



(b) With retracted lips



(c) Initial OPG

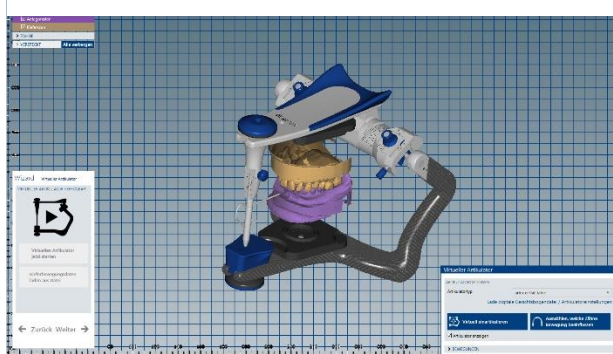


A treatment plan was finalised after intense discussions with the patient regarding the aesthetical aspects of possible solutions and an individual consideration of the prognosis of all teeth and the financial framework. Especially an ethical consideration of the necessary extractions in the overall view of all information was a significant part of finding the right way forward. It was decided to remove all teeth in the upper jaw and to immediately insert six implants and to carry out surgical periodontal debridement in the lower jaw.

Due to financial constraints it was planned to preserve the teeth in the lower jaw for as long as possible and only restore them when needed with a concept based on four implants. Comparable to the first patient case above, it was determined that the majority of the treatment would be carried out under deep sedation. The treatment planning process was carried out in the same way as the first patient case: A cone beam computer tomography (CBCT), a digital scan of the initial situation and a photo status were taken (Figures 14a and 15a-f).

Figure 14

(b) The digitally designed initial situation in the virtual articulator



(a) The digital design of the temporary

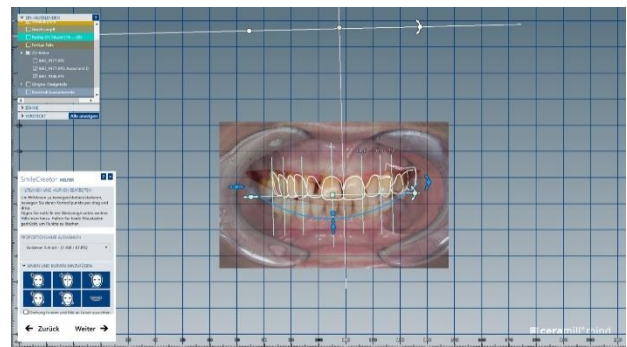
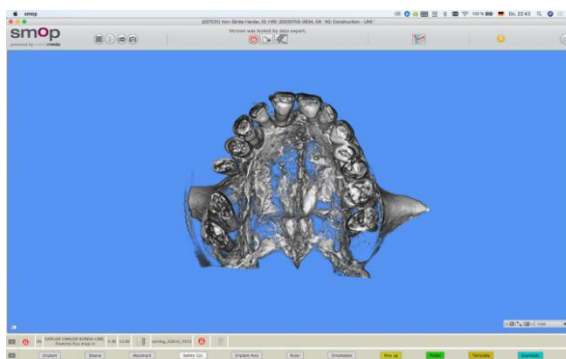
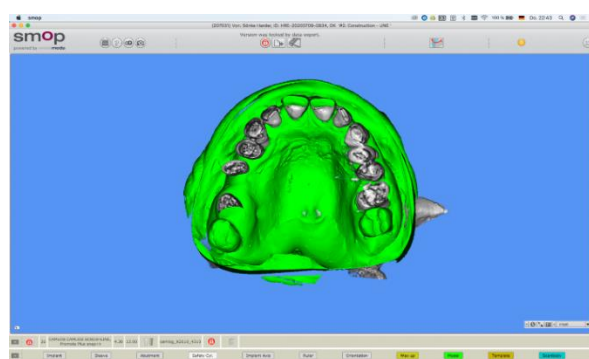


Figure 15

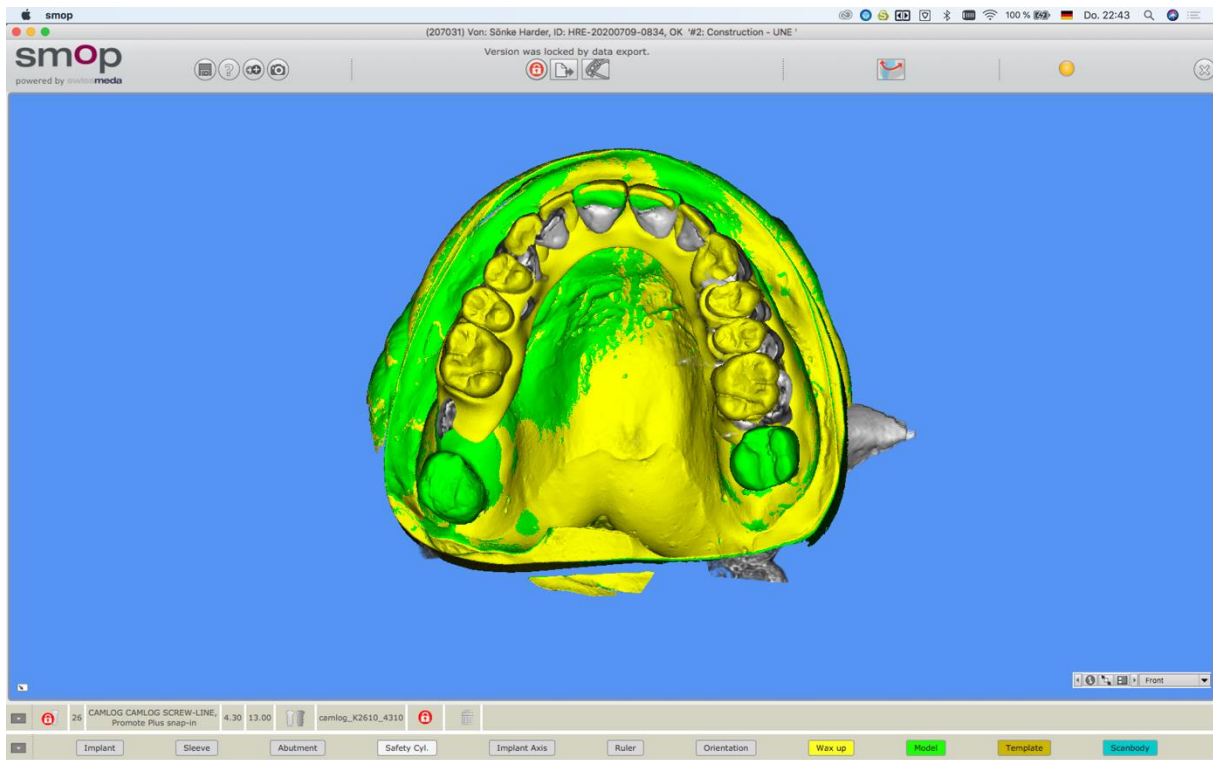
(b) Implant planning with uploaded CBCT



(a) Superimposed initial situation

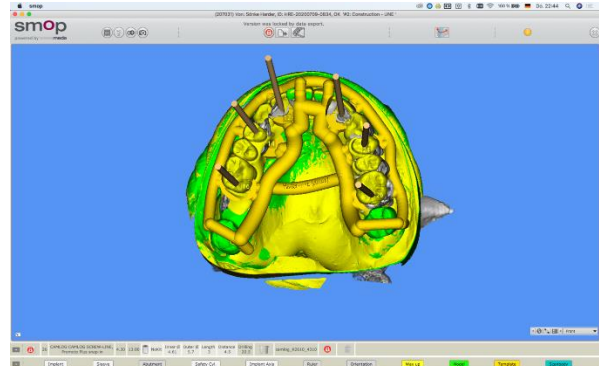
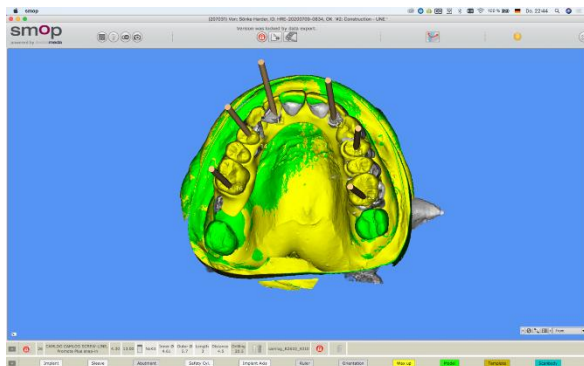


(c) Superimposed wax-up / set-up

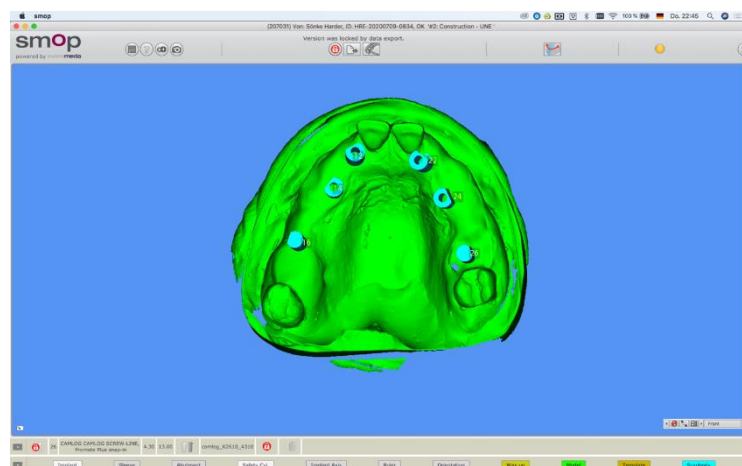


(e) Planning of the implant position shown here with the alignment of the mesostructure

(d) The printed guide template



(f) The scan-body model used by the technician to produce and adjust the PMMA temporary



The collected data was then processed in three ways:

1. The digital implant planning by the dentist (Figure 15a-15d)
2. “Smile design” by the dentist (Figure 14b)
3. The dental technician transferred the digital preparation by the dentist from 1. and 2. into the analogue world (models, drilling template, preparation of the temporaries)

For this it is important to know how the transfer and communication between dentist and dental technician works. The sequence can be seen in Figures 14 and 15. The dental technician firstly creates models from the digital data set of the initial situation, which he uploads into the virtual articulator (Figure 14a). Then all teeth are erased from the initial model and a digital set-up of the final situation is created according to the digital instructions from the dentist (“smile design”). The data are then loaded into the implant planning program.

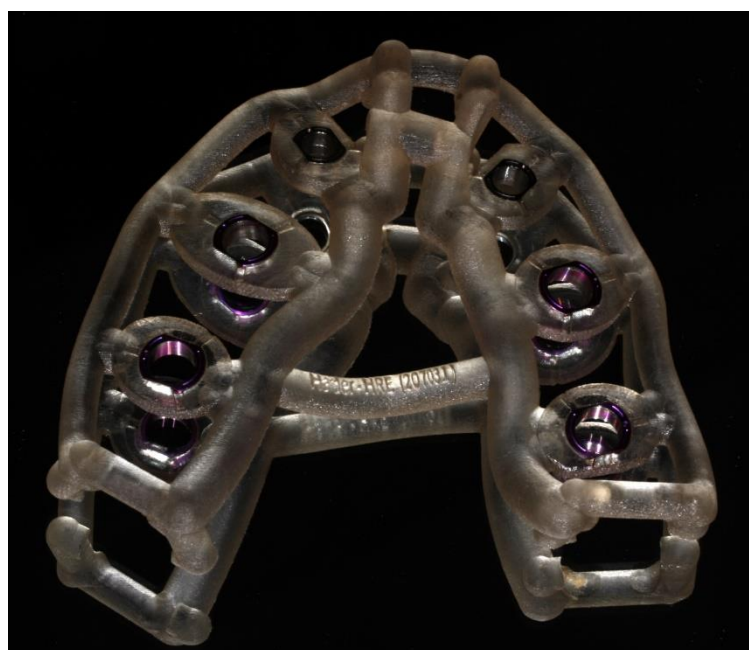In chronological order:

1. CBCT
2. Model with erased teeth
3. Digital set-up
4. Opposite jaw

The dentist then creates the surgical implant plan using a software program (SMOP, Figure 15a-g). The position of the virtual scan-bodies is exported via an STL file. The dental technician treats the virtual scan-body model like an intraoral digital impression and can now ideally adapt the temporary to the planned implant position before milling. Additionally, models (printed in-house) and the drilling template (Camlog Dedicam, Wimsheim; Figure 16) were printed.

Figure 16

(a) The printed implant guide



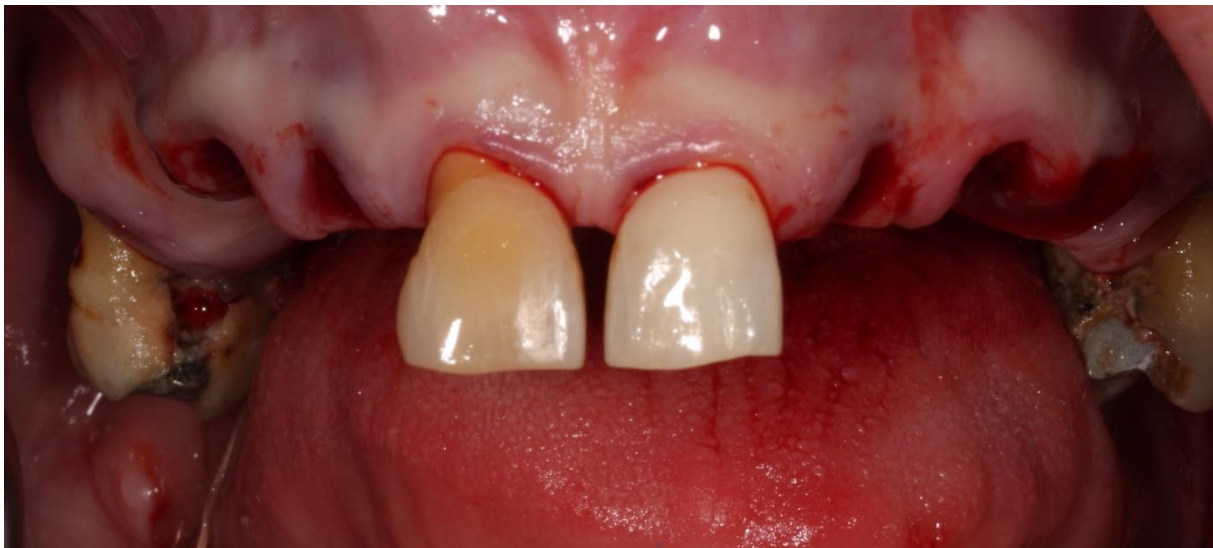In a three-hour operation under deep sedation teeth 12-17 and 22-27 were removed from the upper jaw (Figure 17a; teeth 11, 21, 17 and 27 are required for fixation of the surgical template) and surgical open debridement was performed in the lower jaw. A mucoperiosteal flap was prepared in the upper jaw and the implant cavities were prepared using the implant guide (Figure 17a). After placing the implants guided (Camlog Progressive Line; Figure 17c) with a torque between 50 - 70 Ncm the mesostructure was screwed in and the remaining teeth 11, 21, 17 and 27 were removed. The extraction sockets were filled or covered with xenogeneic bone (BioOss) and membranes (Osseoguard).

Similar to the first case after suturing, an open tray impression (Permadyne) and a bite (R-SI-Line) was taken. A postoperative OPG was taken after the patient woke up from the sedation (Figure 17d). The upper jaw implant model was fabricated in about one hour and titanium link abutments were inserted into the upper jaw temporary restoration (Figure 17e). Four hours after the start of the operation, the temporary screw retained bridge could be inserted with a torque of 10 Ncm (Figure 18a and b). The access to the screw holes was covered with PTFE and composite (Tetric flow, Ivoclar, Schaan, Lichtenstein).

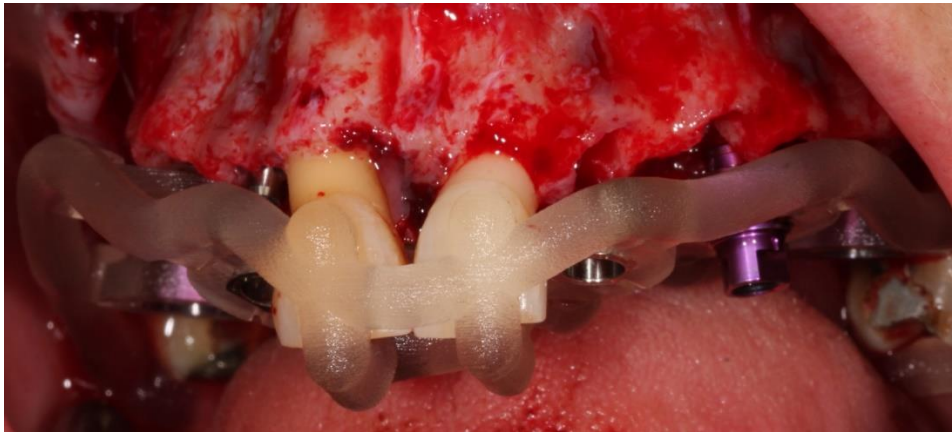After a further three weeks, the final restoration was planned to be inserted (NEM framework individually veneered with acrylic). The patient has to participate in a six-monthly recall.

Figure 17
Surgery with,

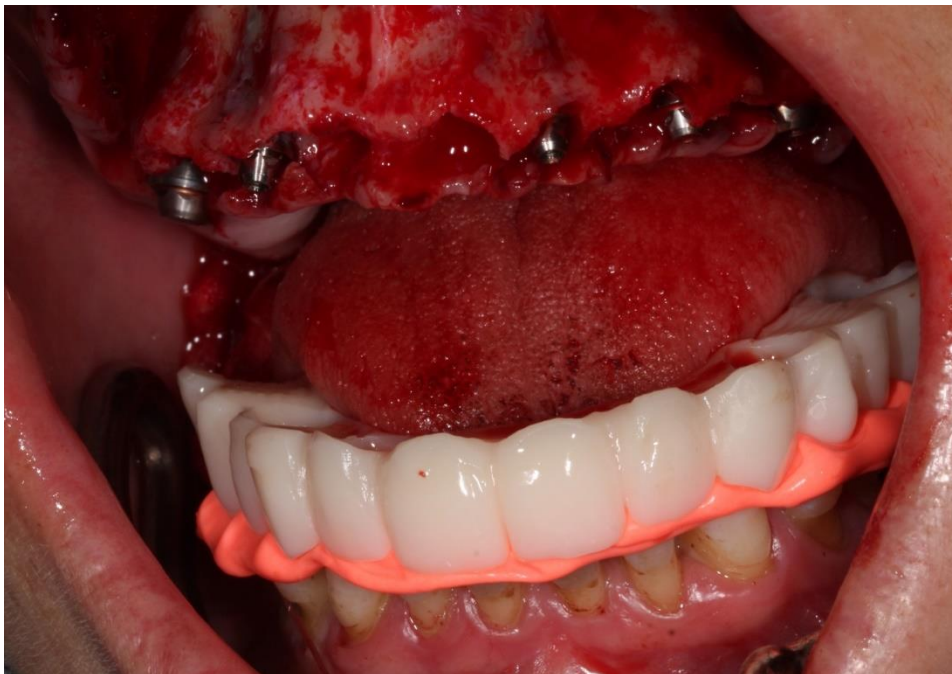(a) Extracted teeth 12-16 and 22-26



(b) Implant guide template inserted



(c) The six placed implants and the temporary ready for taking the bite



(d) Postoperative OPG and temporary ready for placement

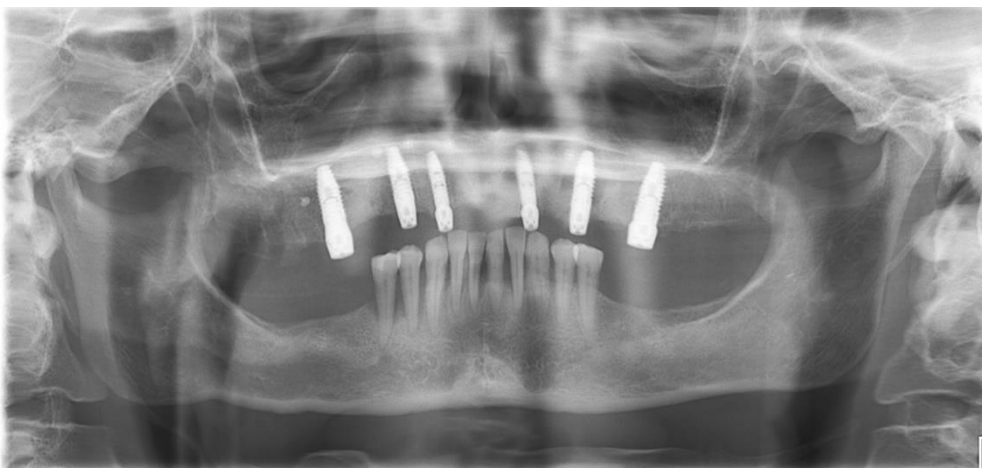
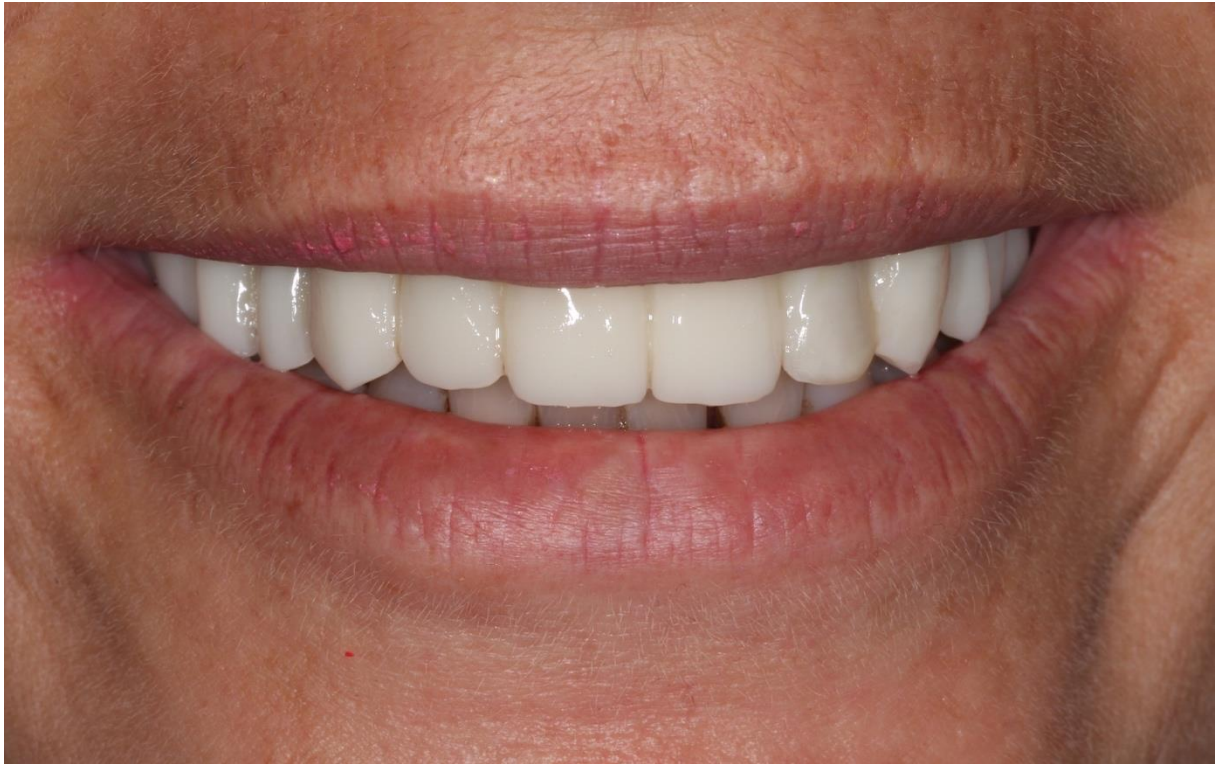
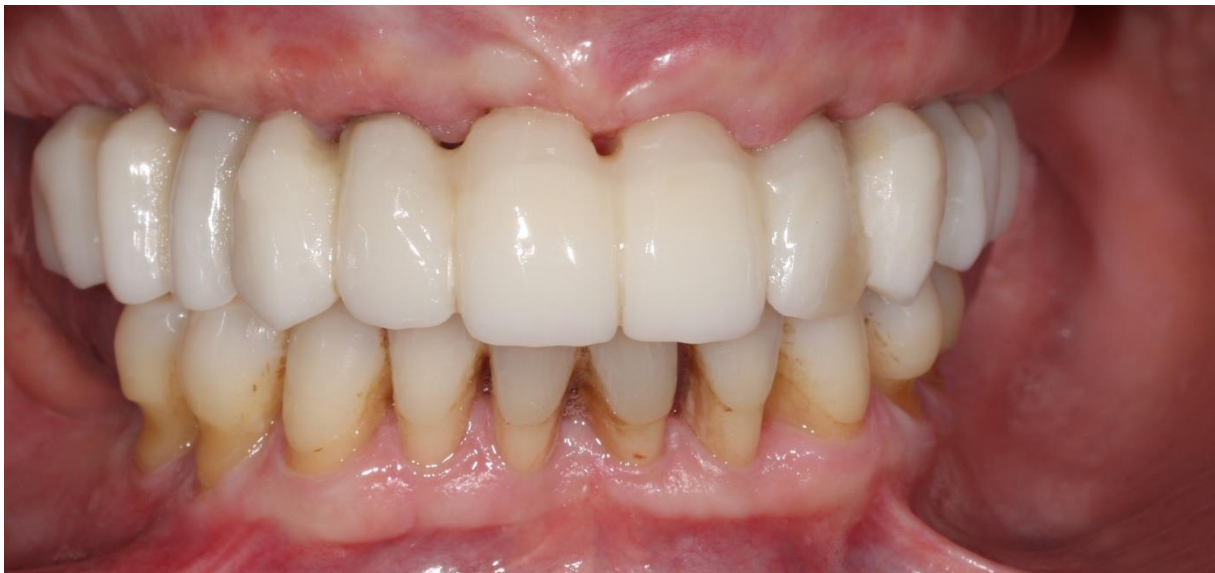Figure 18

Situation three weeks after the surgery with (a) patient smiling and (b) with retracted lips. The permanent restoration will be placed a few weeks later.

(a) Patient smiling



(b) With retracted lips



Discussion and Conclusion

As implant based restorations offer enormous oral health related quality of life compared to removable dentures patients enquire about this treatment option more [5, 6]. As already mentioned in the introduction, the time span for conventional implant restorations including the incorporation of the definitive restoration can be estimated to be between 3 months and 1.5 years (in cases with large augmentations and / or long implant healing times) [7, 8]. This circumstance often leads to an increased level of stress for the patients who, after the strenuous surgical pre-treatment phase, can no longer muster the patience for the final prosthetic restoration [9]. This is why it is important to consider less time-consuming and more cost-effective alternatives such as the Comfour[®] procedure, especially for complex two-stage bone augmentations and implantations [10, 11]. With this method, toothless patients or patients with teeth that cannot be preserved can receive new fixed teeth in a relatively short time span [10-12].

In the literature, the implants and prostheses used in this way show a survival rate that is comparable to the conventional procedure [11, 13, 14]. However, there must be an open ethical discussion with the patient about the sacrifice of otherwise usable teeth for this concept [12]. The consideration of whether healthy teeth are extracted is not only a dental-ethical one, but also a functional one [12]. The tactility of a purely implant-supported restoration is about ten times less than that of a restoration with tooth involvement [15]. This consideration should be taken into account when patient receive implant only supported restorations.

With regard to the selection of materials, an individually milled and fully veneered non-precious metal framework was used in the above cases. According to current studies, metal frameworks veneered with ceramic show fewer ceramic fractures (chipping) compared to fixed restorations with zirconium dioxide frameworks [16, 17]. Small chipping of the ceramic veneer surface was detected in a 3-year follow-up in 25% of the zirconium oxide ceramic and 19.4% of the metal-ceramic restorations [16, 18].

A milled and individually painted full zirconia restoration could be considered as an inexpensive alternative [19], but is only recommended to a limited extent in the case of natural opposing dentition, as the antagonists may be chipping [20]. In our experience the best material combination is a non-noble alloy framework combined with industrially prefabricated composite veneers.

With regard to the number of implants, guidelines usually still recommend four implants in the upper jaw to be restored by removable restorations and only suggest a fixed restoration when there are six osseointegrated implants [21]. Six implants are usually fitted with a horseshoe-shaped superstructure in order to achieve greater stability. The insertion of eight implants in the toothless jaw enables the design of smaller segments up to single crowns, which in case of ceramic fractures or implant losses offers better chances of repair and expandability of the denture and reduces the tension in the framework and improves passive fit.

Joining the impression posts (e.g. with composite and a wire) is recommended especially for restorations with large frameworks,. This impression technique reduces stress in the framework and improves the accuracy of fit of the screw retained bridge [22, 23].

Guided vs. unguided implantation

Please allow us a personal note at the beginning of this chapter. Interestingly, both authors come from completely different backgrounds on the subject of navigated implantology. Dr. Harder has been deeply involved in the subject for quite some time [4] and has put this kind of methodology into practice for us. Dr. Mehl, on the other hand, relied more on human precision. What a mistake!

Despite more than 1000 implants placed, it becomes quite obvious that humans can never achieve the precision of fully developed and tested machines. In 2021, navigated implantology and digital planning have reached such a level that makes it almost imperative to work with them.

A prevalent preconception - prompted by old studies – is that the height deviation and the axis inclination of the navigated implants were worse than those of manually placed implants [24, 25]. Studies from 2009 reported mean deviations in the implant position of 1 mm at the entry point (implant shoulder) and 1.6 mm at the implant tip (apex), as well as a height deviation of 0.5 mm and a deviation in the axis inclination of 5–61° [25].

In another study from 2012, a deviation of 0.99 mm (from 0 to 6.5 mm) at the entry point and of 1.24 mm (from 0 to 6.9 mm) at the apex, as well as a deviation in the angulation of 3.81 degrees (from 0 to 24.9 degrees) were determined [24]. In the meantime the picture has completely changed.

The fully guided implant surgery approach achieved significantly lower 3D deviations between the planned and the actual implant position with 0.22 ± 0.07 mm (2 mm sleeve-bone distance) than the partially guided 0.69 ± 0.15 mm and the freehand placement 0.80 ± 0.35 mm ($P \leq 0.001$ [26]). However, it is important to keep the distance between the guide sleeve and the crestal bone as small as possible. Another advantage of guided implantation is the - in addition to forensic aspects that should not be neglected - reduction in chair time and the possibility of having temporary restorations ready for use chair-side before immediate implantation. The prerequisites for this treatment method are detailed diagnostics and a great collaboration between patient, dental technician and dentist [2, 27-29].

Literature

- [1] T. Kerschbaum, Langzeitüberlebensdauer von Zahnersatz. Eine Übersicht. [Article is in German], *Die Quintessenz* 55(10) (2004) 1113-1126.
- [2] C. Mehl, M. Kern, S. Freitag-Wolf, M. Wolfart, S. Brunzel, S. Wolfart, Does the Oral Health Impact Profile questionnaire measure dental appearance?, *Int J Prosthodont* 22(1) (2009) 87-93.
- [3] C.J. Mehl, S. Harder, M. Kern, S. Wolfart, Patients' and dentists' perception of dental appearance, *Clin Oral Investig* 15(2) (2011) 193-9.
- [4] S. Wolfart, S. Harder, S. Reich, I. Sailer, V. Weber, *Implantat prosthodontiocs - A patient oriented concept*, Quintessence - Berlin 2014.2014.
- [5] S. Wolfart, K. Wolf, S. Brunzel, M. Wolfart, A. Caliebe, M. Kern, Implant placement under existing removable dental prostheses and its effect on masticatory performance, *Clin Oral Investig* (2016).
- [6] S. Wolfart, K. Braasch, S. Brunzel, M. Kern, The central single implant in the edentulous mandible: improvement of function and quality of life. A report of 2 cases, *Quintessence Int* 39(7) (2008) 541-8.
- [7] G.A. Zarb, A. Schmitt, The longitudinal clinical effectiveness of osseointegrated dental implants: the Toronto study. Part I: Surgical results, *The Journal of prosthetic dentistry* 63(4) (1990) 451-7.
- [8] G.A. Zarb, A. Schmitt, Osseointegration and the edentulous predicament. The 10-year-old Toronto study, *Br Dent J* 170(12) (1991) 439-44.
- [9] P. Davies, I. Payne, The evaluation of relative stress levels associated with common dental procedures, *Dent Update* 7(6) (1980) 339-42.
- [10] P. Malo, M. de Araujo Nobre, J. Borges, R. Almeida, Retrievable metal ceramic implant-supported fixed prostheses with milled titanium frameworks and all-ceramic crowns: retrospective clinical study with up to 10 years of follow-up, *J Prosthodont* 21(4) (2012) 256-64.
- [11] P. Malo, M. de Araujo Nobre, A. Lopes, The prognosis of partial implant-supported fixed dental prostheses with cantilevers. A 5-year retrospective cohort study, *Eur J Oral Implantol* 6(1) (2013) 51-9.
- [12] C. Mehl, S. Harder, "Feste dritte Zähne" an einem Tag - ein Fallbericht, *ZMK* 5 (2015) 1-7.
- [13] U. Lekholm, K. Grondahl, T. Jemt, Outcome of oral implant treatment in partially edentulous jaws followed 20 years in clinical function, *Clinical implant dentistry and related research* 8(4) (2006) 178-86.
- [14] P. Malo, M. de Araujo Nobre, A. Lopes, S.M. Moss, G.J. Molina, A longitudinal study of the survival of All-on-4 implants in the mandible with up to 10 years of follow-up, *Journal of the American Dental Association* 142(3) (2011) 310-20.
- [15] R. Jacobs, D. van Steenberghe, Comparative evaluation of the oral tactile function by means of teeth or implant-supported prostheses, *Clin Oral Implants Res* 2(2) (1991) 75-80.
- [16] I. Sailer, J. Gottnerb, S. Kanelb, C.H. Hammerle, Randomized controlled clinical trial of zirconia-ceramic and metal-ceramic posterior fixed dental prostheses: a 3-year follow-up, *Int J Prosthodont* 22(6) (2009) 553-60.
- [17] I. Sailer, A. Feher, F. Filser, L.J. Gauckler, H. Luthy, C.H. Hammerle, Five-year clinical results of zirconia frameworks for posterior fixed partial dentures, *Int J Prosthodont* 20(4) (2007) 383-8.
- [18] I. Sailer, N.A. Makarov, D.S. Thoma, M. Zwahlen, B.E. Pjetursson, All-ceramic or metal-ceramic tooth-supported fixed dental prostheses (FDPs)? A systematic review of the survival and complication rates. Part I: Single crowns (SCs), *Dent Mater* 31(6) (2015) 603-23.
- [19] C. Mehl, Vollanatomisch gefräster Zahnersatz aus Zirkoniumdioxid – die Zukunft?, *ZMK* 5 (2015) 1-8.
- [20] B. Limmer, A.E. Sanders, G. Reside, L.F. Cooper, Complications and patient-centered outcomes with an implant-supported monolithic zirconia fixed dental prosthesis: 1 year results, *J Prosthodont* 23(4) (2014) 267-75.
- [21] J. Schley, H. Terheyden, S. Wolfart, *Implantatprothetische Versorgung des zahnlosen Oberkiefers*, S3-Leitlinie, AWMF-Registernr. 083-010 (2013).
- [22] A. Mehl, R. Koch, M. Zaruba, A. Ender, 3D monitoring and quality control using intraoral optical camera systems, *International journal of computerized dentistry* 16(1) (2013) 23-36.
- [23] C. Mehl, *Prothetik im digitalen Zeitalter*, *Special Tribune* 9 (2014) 18-22.
- [24] N. Van Assche, M. Vercruyssen, W. Coucke, W. Teughels, R. Jacobs, M. Quirynen, Accuracy of computer-aided implant placement, *Clin Oral Implants Res* 23 Suppl 6 (2012) 112-23.
- [25] D. Schneider, P. Marquardt, M. Zwahlen, R.E. Jung, A systematic review on the accuracy and the clinical outcome of computer-guided template-based implant dentistry, *Clin Oral Implants Res* 20 Suppl 4 (2009) 73-86.
- [26] A. Guentsch, L. Sukhtankar, H. An, P.G. Luepke, Precision and trueness of implant placement with and without static surgical guides: An in vitro study, *The Journal of prosthetic dentistry* (2020).
- [27] C. Mehl, S. Harder, J. Lin, O. Vollrath, M. Kern, Perception of dental esthetics: influence of restoration type, symmetry, and color in four different countries, *Int J Prosthodont* 28(1) (2015) 60-4.



[28] C. Mehl, S. Harder, J. Lin, O. Vollrath, M. Kern, Perception of dental esthetics in different cultures, *Int J Prosthodont* 28(1) (2015) 60-4.

[29] C. Mehl, S. Harder, S. Wolfart, O. Vollrath, A. Trinkler, H.J. Wenz, M. Kern, Influence of dental education on esthetic perception, *Int J Esth Dent* 10(3) (2015) in press.